

Contact Information

Faizi A. Siddiqi, MD, FACS

Chief, Pediatric Plastic/
Craniofacial Surgery
University of Utah
Division of Plastic Surgery
30 North 1900 East, 3B400
Salt Lake City, Utah 84132

Phone: (801) 581-5132

Fax: (801) 581-5794

faizi.siddiqi@hsc.utah.edu

www.utahplasticsurgery.org



John R.W. Kestle, MD

Chief, Division of Pediatric Neurosurgery
Professor of Neurosurgery
Adjunct Professor of Pediatrics
University of Utah
Department of Neurosurgery
175 North Medical Drive East
Salt Lake City, UT 84103

Director, Resident Training
Primary Children's Medical Center

Phone: (801) 662-5340

Fax: (801) 662-5370

john.kestle@hsc.utah.edu

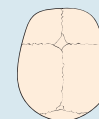Head Shapes

Newborns often have an abnormally shaped head. This is part of the natural birthing process as the head changes its shape to pass through the birth canal. Following birth, head shape returns to normal within several weeks. However, when head asymmetry persists, it is important to differentiate deformational **plagiocephaly** from **craniosynostosis**.

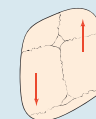The skull is made up of several pieces of bone joined together at growth centers or "sutures." In craniosynostosis, a cranial suture closes too soon resulting in an abnormal head shape, face, and orbits. Craniosynostosis occurs 1 in 2000 live births, usually affecting more boys than girls. Surgery is performed to correct head shape and decrease the risk of raised pressure on the brain.

Plagiocephaly

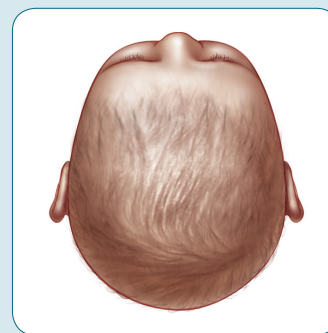
Helmet therapy is recommended at 6 to 7 months of age for moderate-to-severe cases unresponsive to repositioning, and cases associated with torticollis.



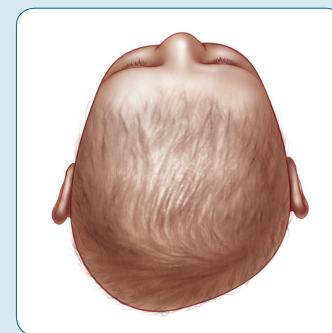Normal



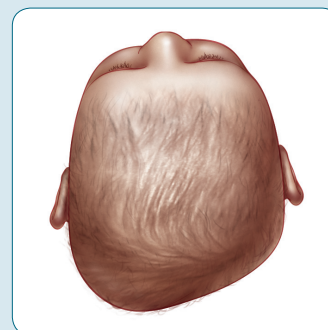
Severe Plagiocephaly



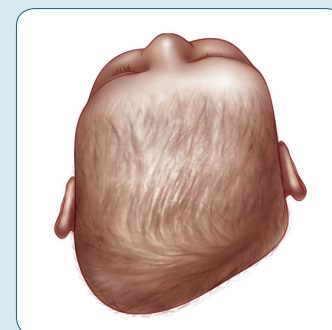
Normal



Mild Plagiocephaly



Moderate Plagiocephaly



Severe Plagiocephaly



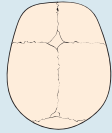
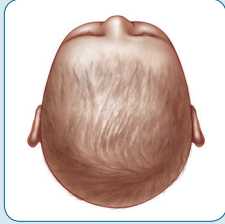The University of Utah
Division of Plastic Surgery



IntermountainSM
Primary Children's
Medical Center

Primary Children's Medical Center
100 Mario Capecchi Drive, Salt Lake City, Utah 84113

Craniosynostosis

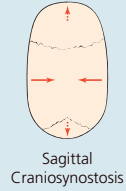
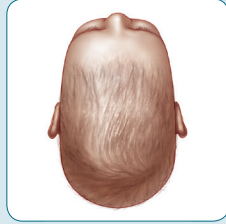

Normal

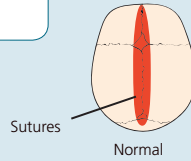
Normal Head Shape

Sagittal Craniosynostosis

Long narrow skull.
Most common craniosynostosis.



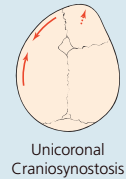
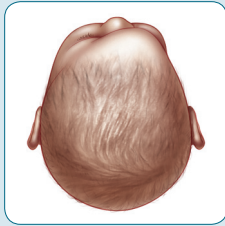Sagittal Craniosynostosis



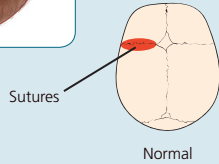
Normal

Unicoronal Craniosynostosis

Flattening of forehead and brow.
Second most common.



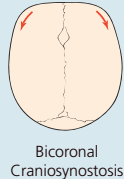
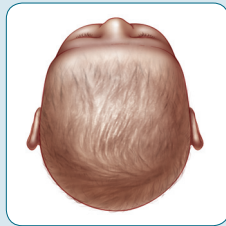Unicoronal Craniosynostosis



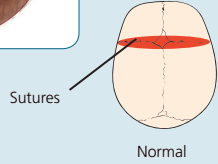
Normal

Bicoronal Craniosynostosis

Tall flat, retruded forehead.
Usually associated with a syndrome.



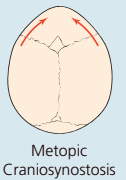
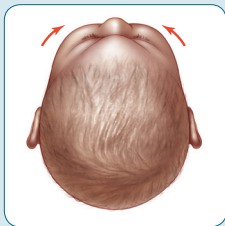
Bicoronal Craniosynostosis



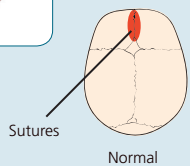
Normal

Metopic Craniosynostosis

Triangle shaped skull. Prominent midline ridge.
Third most common.



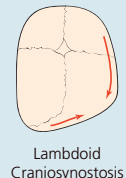
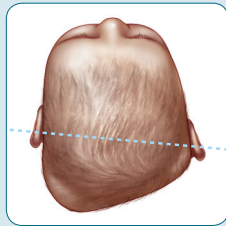
Metopic Craniosynostosis



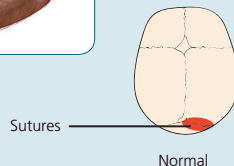
Normal

Lambdoid Craniosynostosis

Can be confused with deformational plagiocephaly.



Lambdoid Craniosynostosis

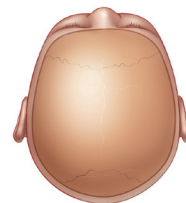
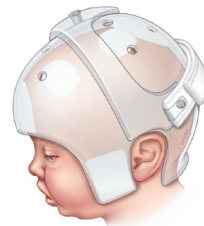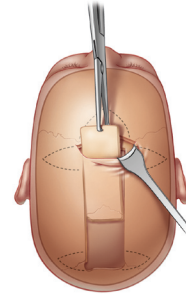
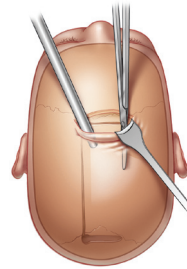


Normal

Surgery for Craniosynostosis

The type of surgery depends upon the age of diagnosis which is confirmed by CAT scan. Surgeries are either a minimally invasive endoscopic assisted strip craniectomy for infants less than 4 months old, or a more involved orbital and cranial vault reconstruction for older infants. Advantages of the endoscopic technique include shorter operative time, shorter hospitalization, less blood loss, less scarring, less swelling, and a smooth round head.

Surgery before 4 months



Surgery after 4 months

